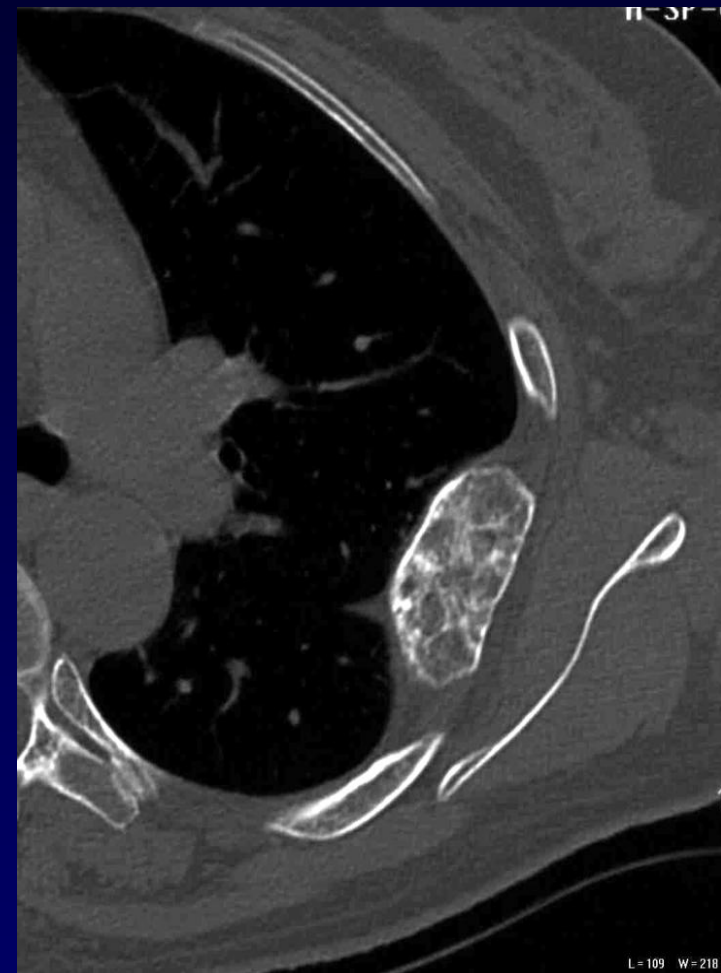
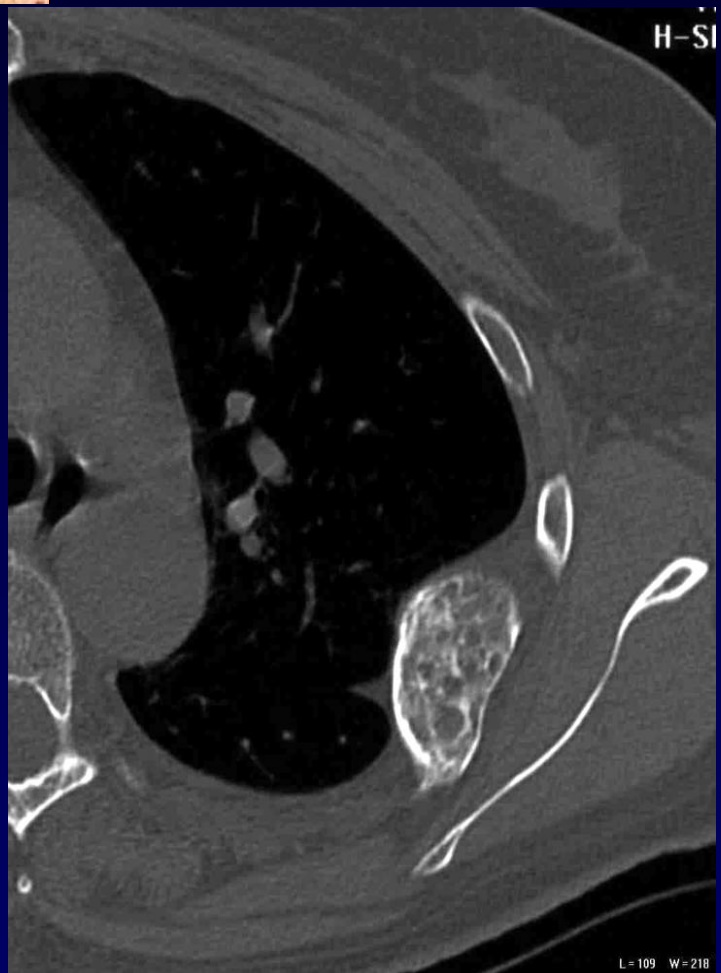




J GIRON

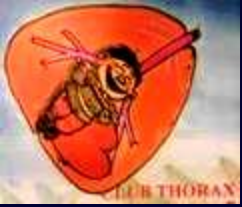Femme de 55 ans

Asymptomatique





Diagnostic ?



**Syndrome tumoral osseux costal avec caractères de
bénignité**

**Dysplasie fibreuse
probable**